



Diaphragmatic Hernias: A Cause of Unilateral Loss of The Cardiophrenic Sinus Angle

Kardiyofrenik Sinus Acı Keskinliğinin Tek Taraflı Kaybının En Sık Nedeni: Diyafragmatik Herniler

Diaphragmatic Hernias

Elcin Zan¹, Asli Tanrivermis Sayit², Aydın Kurt³, Ali Ipek⁴

¹Department of Radiology, Russell H. Morgan The Johns Hopkins Hospital, Baltimore, ABD,

²Department of Radiology, Samsun Gazi State Hospital, Samsun, Turkey,

³Department of Radiology, Diskapi Yildirim Beyazit Education and Research Hospital, Ankara, Turkey,

⁴Department of Radiology, Ankara Atatürk Education and Research Hospital, Ankara, Turkey

Özet

Amaç: Kardiyofrenik boşluk mediasteninin en bazal kısmı olup kalp, diyafragma ve göğüs duvarı ile çevrilidir. Kardiyofrenik boşluk yağ dokusu ile dolu olup keskin sınırlıdır. Ancak enfeksiyonlar, inflamasyon ve diyafragmatik herniler gibi bazı yer kaplayan lezyonlar kardiyofrenik sinuste küntleşmeye neden olabilir. Biz bu çalışma ile kardiyofrenik sinuste küntleşmeye neden olan diyafragmatik hernilerin insidansını bulmayı amaçladık. **Gereç ve Yöntem:** 983 çok kesitli toraks bilgisayarlı tomografisi tek taraflı kardiyofrenik yağlı doku artışı açısından kliniğimizde araştırılmıştır. Tek taraflı (sağ/sol) küntleşmesi olan 200 olgu çalışmaya dahil edilmiştir. Tüm olgularda dansite ölçümü yapılarak kardiyofrenik sinuste yağ dokusu varlığı teyit edilmiştir. Yapılan istatistiksel analiz ile yaş, cinsiyet, sağ ve sol taraflı atelektazi ve eşlik eden diyafragmatik herni varlığı açısından anlamlı farklılık olup olmadığı araştırılmıştır. **Bulgular:** Çalışmaya dahil edilen olguların 107'si kadın (%53.5), 93'ü erkek (%46.5) olarak saptandı. Olguların %28'inde diyafragmatik herni saptandı. Diyafragmatik hernisi olan olguların %31'i bayan, %24'ü erkek olarak saptanmış olup Morgagni herni insidansı %14.5 dir. Bayanlarda erkeklere göre daha sık saptanmış olup istatistiksel olarak anlamlı bulunmuştur ($p<0.05$). Tüm olgularda en sık sağda (%89) izlenmiştir. **Sonuç:** Diyafragmatik defektler sıklıkla asemptomatik olup ileri yaş hasta grubunda daha sık saptanmaktadır. Tek taraflı kardiyofrenik sinuste küntleşmesi olan olgularda diyafragmatik herniler ayırıcı tanıda düşünülmelidir. Diyafragmatik herni komşuluğundaki akciğer dokusunda atelektazi çok sık izlenmektedir. Ancak atelektazinin çok çeşitli nedenleri olmasından dolayı diyafragmatik herni tanısındaki yönlendirici değeri düşüktür.

Anahtar Kelimeler

Çok Kesitli Bilgisayarlı Tomografi; Kardiyofrenik Sinus; Morgagni Hernisi

Abstract

Aim: Cardiophrenic space is the most basal portion of the mediastinum and surrounded by heart, diaphragm and chest wall. Cardiophrenic space full with fatty tissue shows a sharp angles. However, some space-occupying lesions, infections, inflammations and diaphragmatic herniation can be the cause of the blunt cardiophrenic sinus angle. The aim of this study is to determine the incidence of loss of the cardiophrenic sinus angle due to diaphragmatic hernias. **Material and Method:** We retrospectively evaluated 983 consecutive chest multidetector computed tomography images for presence of unilaterally increased fat tissue. 200 patients who had blunting in the cardiophrenic (right or left) sinus were included in the study. Density measurements proved the presence of adipose tissue in the cardiophrenic sinus in all patients. The relationship between age, gender and right or left sided atelectasis and associated diaphragmatic hernias were statistically analyzed. **Results:** 107 patients were female (53.5%) and 93 (46.5%) were male. 28% of patients had diaphragmatic hernia. 31% of females and 24% of males had diaphragmatic hernia. Incidence of the Morgagni hernia was 14.5% and it was significantly higher in females than in males ($p<0.05$) and overall was lateralized 89% to the right. **Discussion:** Diaphragmatic defects are usually asymptomatic and asymptomatic diaphragmatic hernias are not rare in older population. In patients with the unilateral cardiophrenic sinus blunting, diaphragmatic hernias must be included in the differential diagnosis. Neighboring atelectasis in the lung parenchyma near the diaphragmatic hernia was a common finding. But it had a low yield for the diagnosis of diaphragmatic hernia.

Keywords

Multidetector Computed Tomography; Cardiophrenic Sinus; Morgagni Hernia

DOI: 10.4328/JCAM.2567

Received: 16.05.2014 Accepted: 10.06.2014 Printed: 01.01.2016

J Clin Anal Med 2016;7(1): 42-5

Corresponding Author: Asli Tanrivermis Sayit, Samsun Gazi State Hospital, Department of Radiology, Samsun, Türkiye.

T.: +90 3122912525 F.: +90 3122912707 E-Mail: draslitanrivermissayit@gmail.com

Introduction

Cardiophrenic space is the basal portion of the mediastinum and is bordered by base of the heart, diaphragm and chest wall [1]. Under normal conditions, cardiophrenic space is filled with adipose tissue and has a sharp angle.

Loss of the cardiophrenic sinus angle may be due to space-occupying lesions, infection, inflammation, increased fat tissue in the pericardial space or diaphragmatic herniation. The evaluation should be obtained by multidetector computed tomography (MDCT) for the differential diagnosis and treatment guide [1-5]. The aim of this study is to determine the incidence of loss of the cardiophrenic sinus angle due to diaphragmatic hernia.

Material and Method

This retrospective study was approved by our institutional review board. 983 consecutive chest MDCTs performed at our department were evaluated for the presence of one-sided increased cardiophrenic fat tissue. 200 patients who had blunting in the cardiophrenic (right or left) sinus due to fat tissue and associated atelectasis, were included in the study. Presence of associated parenchymal atelectasis in the relevant side was the clue for us which indicates accumulated adipose tissue is abnormally large enough to cause compression atelectasis in the neighboring lung tissue. Then we looked for the continuation of diaphragm in sagittal and coronal planes using multiplanar reformatted (MPR) images. Gender, age and chest MDCT indications were noted for all patients.

The MDCT equipment was a 64-slice Toshiba Aquilion, Chicago, USA. The imaging and reconstruction parameters were as follows; collimation, 24x1.2; pitch, 1.4; 120 kV;125-323 mAs; slice width, 1 mm; rotation time, 0.5 sec. mAs were given automatically based on the patient's body weight. Chest MDCT was performed in the supine position with or without iodinated contrast agent. The total lung parenchyma on each side was evaluated. Chest computed tomography (CT) images were displayed with a mediastinal window setting (window width, -145/+195 HU) for highlighting the cardiophrenic sinus fat tissue (<-50 HU). All patients were evaluated for the cardiophrenic sinus fat tissue thickness (figure 1), fat tissue density (figure 2), atelectasis (figure 1-3) and diaphragmatic hernia.

Two radiologists did the measurements independently and consensus was made in discrepant cases. Density measurements proved the presence of adipose tissue in the cardiophrenic sinus (HU<50, figure 2) in all patients. The cardiophrenic fat tissue thickness was measured perpendicular to the long axis of the heart (figure 1). Relationship between age, gender and right or left sided atelectasis and associated hernia were statistically analyzed.

Statistical analyses were performed using Statistical Package for Social Sciences, version 15.0 (SPSS, Inc., Chicago, IL, USA) applying Chi-square test.

Results

Out of 200; 107 patients were female (53.5%) and 93 (46.5%) were male. The 87% of the chest CT indications was to rule out the tumoral or infectious pathologies causing cardiophrenic angle blunting in PA chest roentgenograms. Average age was 61.7 years for all patients (61.2 years in males and 62.2 years

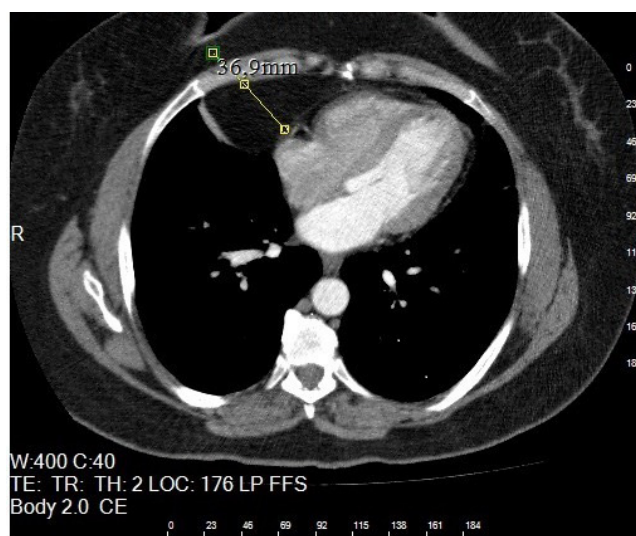


Figure 1. Right cardiophrenic soft tissue thickness were measured to be perpendicular to the long axis of the heart with manually.

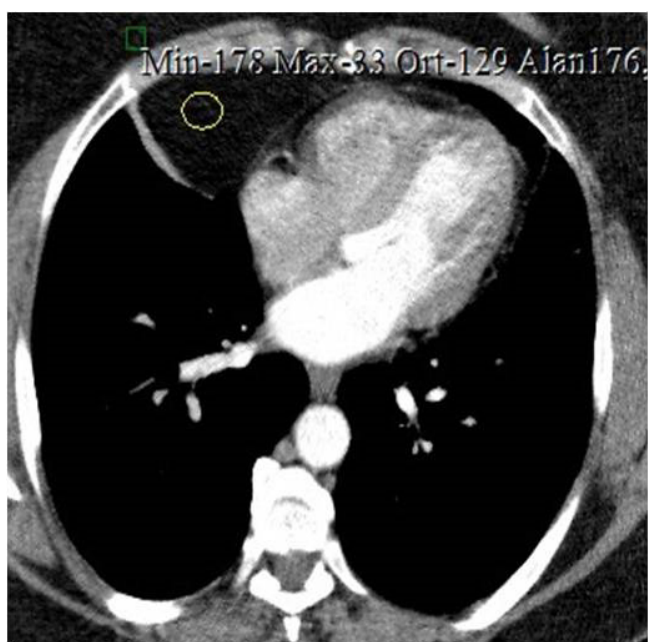


Figure 2. (-) 129 HU density (fat) were measured in the right cardiophrenic sinus and compression atelectasis were noted due to cardiophrenic fatty tissue in the axial contrast enhanced thorax CT.

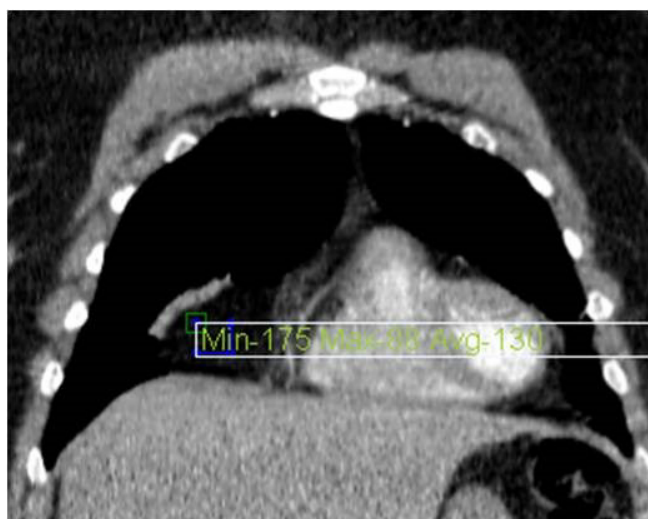

Figure 3. Coronal enhanced thorax CT revealed that atelectasis due to increased right cardiophrenic fatty tissue (- 130 HU).

in females) (table 1).

Average thickness of the cardiophrenic fat tissue was 32.2 mm

Table 1. The mean age and gender distribution of the patients.

Gender	Number	Mean Age	ss
Female	107 (53.5%)	62.2	15.7
Male	93 (46.5%)	61.2	14.5
Total	200	61.7	15.1

on the right and 28.2 mm on the left. When gender was taken into account, the cardiophrenic sinus fat tissue thickness of the female patients was 25.4 mm on the left and 30.9 mm on the right. As for the male patients, the cardiophrenic sinus fat tissue thickness was 30.8 mm on the left and 34.2 mm on the right (table 2). Overall, atelectasis was located 79% on the right side, and 21% on the left side. However, based on the gender,

Table 2. Types of the diaphragmatic hernia and the distribution according to gender.

Diaphragmatic hernia	Ratio	
Morgagni hernia	14,5% (29/200)	Female: 17.7% (19/107) Male: 10.7% (10/93)
Local diaphragmatic hernia	13,5% (27/200)	Female: 13% (14/107) Male: 13.8% (13/93)
Total	28% (56/200)	Female: 30.8% (33/107) Male: 24.7% (23/93)

atelectasis was detected 81.3% on the right and 18.7% on the left side in female patients. In male patients, atelectasis was detected 76.3% on the right and 23.6% on the left.

28% of patients had diaphragmatic hernia. 31% of females and 24% of males had diaphragmatic hernia (table 3). The lateralization was to the right on 78.5% and to the left on 11.5%. Incidence of the Morgagni hernia in our cohort was 14.5% (29/200). 19 /29 (65.5%) were female. So, Morgagni hernia was significantly higher in females than in males ($p<0.05$) and overall 89% was lateralized to the right.

Right sided diaphragmatic hernia were dominant for all age and gender groups. However, none of our female patient ≤ 39 year old, demonstrated any diaphragmatic hernia.

Atelectasis with aging followed a constant incline in male patients with diaphragmatic hernia, but we also detected a sharp decline after the age of 80. However, there was no specific pattern for females.

Discussion

The spectrum of pathologies in the cardiophrenic space is quite broad and they can be categorized into four groups: predominantly fat-containing, cystic, solid, and miscellaneous [1]. Predominantly fat-containing pathologies are diaphragmatic hernia, pericardial fat necrosis and fat-containing tumors [1].

Our aim was to detect the overall incidence of diaphragmatic hernia that causes cardiophrenic sinus blunting in patients searched for underlying mass or mass-like pathology on the chest CT. We assessed the fat tissue thickness blunting the cardiophrenic sinus when diaphragmatic hernia was present in those patients.

Diaphragmatic defects can be traumatic, postoperative or con-

genital (the most common) [1]. The 3 basic types of congenital diaphragmatic hernia are posterolateral Bochdalek hernia, anterior Morgagni hernia, and hiatal hernia [6]. Symptomatic Morgagni hernia is a rare condition in any age. The reported incidence of the Morgagni hernia is 1.5% and 7%, respectively, according to the two large studies in the literature and lateralized 90% to the right side [7,8,9]. Incidence of the Morgagni hernia was 14.5% in our study, predominantly on the right side. Our incidence was higher than the literature, but our patient group was not randomised as described before, they were especially selected according to the one-sided cardiophrenic sinus obliteration on chest X-ray.

Previously reported studies were focused on the surgically treated symptomatic cases. Morgagni hernia is usually asymptomatic, but advanced age (especially over 40 years old), increased intraabdominal pressure due to trauma or obesity may become symptomatic. Also, symptoms usually vary according to obstruction of herniated organs. Therefore, the increasing symptomatic cases after the 4th decade and the use of MDCT will increase the detection rate of asymptomatic cases [10]. The mean age of our patient was higher than the other studies in the literature (61.7 years).

Right sided local diaphragm defects were found significantly higher in both females and males (13.5 % (14/107), 13.8% (13/93), respectively) ($p<0.05$). In accordance with the literature, Morgagni hernia was more common in females compared to males (17.7% ; 10.7% respectively), and the difference was statistically significant ($p<0.05$) [7].

The minimum thickness of the cardiophrenic fat that cause atelectasis was higher on the right side (79%), and the difference was statistically significant ($p<0.05$).

CT imaging of the chest should be acquired to confirm the diagnosis when cardiophrenic angle is blunted on chest X-ray [1]. If the diaphragm is intact, cardiac, mediastinal and parenchymal pathologies should be considered. Cardiac pathologies can be classified as pericardial effusion, cardiac lipoma, cardiac masses and epicardial fat tissue [1]. Mediastinal pathologies can be classified as masses, infections and vascular [11,12]. Parenchymal pathologies can be categorized as infections, abscess, empyema, pleural effusion and peripheral lung tumors [1,13]. Presence of fat density in the CT examination restricts the differential diagnosis to diaphragmatic hernia, mediastinal lipomatosis [14], pericardial fat necrosis, lipoma, liposarcoma or fat pad [1]. Associated atelectasis with diaphragmatic hernias is a common entity due to compression as we described in this study.

Older age (average: 61.7 years) was the major limitation of our study.

In conclusion, our study showed that diaphragmatic hernias are not rare in older population. In patients with the unilateral cardiophrenic sinus blunting, diaphragmatic hernias are the main cause. Unilateral atelectasis; associated with increased cardiophrenic fat tissue thickness is common on the right side for both women and men and this finding should raise the suspicion of associated diaphragmatic hernia.

Competing interests

The authors declare that they have no competing interests.

References

1. Pineda V, Andreu J, Caceres J, Merino X, Varona D, Dominquez-Oronoz R. Lesions of the cardiophrenic space: findings at cross-sectional imaging. *Radiographics* 2007;27(1):19-32.
2. Palling MR, Williamson BR. Epicardial fat pad: CT findings. *Radiology* 1987;165(2):335-9.
3. Ozhan C, Kurt A, Arslan H, Zan E. Effects of diffuse hyperaeration on thorax airways. *Firat Med J* 2013;18(3):159-63.
4. Woodring JH, Reed JC. Types and mechanism of pulmonary atelectasis. *J Thorac Imaging*. Spring 1996;11(2):92-108.
5. Gaerte SC, Meyer CA, Winer-Muram HT, Tarver RD, Conces DJ Jr. Fat-containing lesions of the chest. *Radiographics* 2002;22 Spec No: 61-78.
6. Hartman GE. Diaphragmatic hernia. In: Behrman RE, Kliegman RM, Arvin AM, editors. *Nelson Textbook of Pediatrics*. Philadelphia: Saunders; 1996. p. 1161-4.
7. Aabye R. Diaphragmatic hernia. Right-sided subcostosternal type in a patient with large gibbus. *Acta Chir Scand* 1954;108: 6-12.
8. Hoyos A. Foramen of Morgagni hernia. *General Thoracic Surgery*. In: Shields TW, LoCicero J, Carolyn CE, Feins RH, editors. Philadelphia: Lippincott Williams & Wilkins; 2009. p. 719-24.
9. Comer TP, Clagett OT. Surgical treatment of hernia of the foramen of Morgagni. *J Thorac Cardiovasc Surg* 1966;52(4):461-8.
10. Sortey DD, Mehta MM, Jain PK, Aqrawal SR, Gadkari SM, Raqhavan V, et al. Congenital hernia through the foramen of Morgagni (a case report). *J Postgrad Med* 1990;36(2):109-11.
11. Casullo J, Palayew MJ, Lisbona A. General case of the day. Thymolipoma. *Radiographics* 1992;12(6):1250-4.
12. Erdogan E, Demirkazik FB, Gulsun M, Ariyurek M, Emri S, Sak SD. Incidental localized (solitary) mediastinal malignant mesothelioma. *Br J Radiol* 2005;78(933):858-61.
13. Stark DD, Federle MP, Goodman PC, Podrasky AE, Webb WR. Differentiating lung abscess and empyema: radiography and computed tomography. *AJR* 1983;141(1):163-7.
14. Peek DF, Heijmen RH, Ernst SM, Schepens MA. Extensive mediastinal lipomatosis in a patient with severe aortic valve stenosis. *Eur J Cardiothorac Surg* 2002;21(3):564-5.

How to cite this article:

Zan E, Sayit AT, Kurt A, Ipek A. Diaphragmatic Hernias: A Cause of Unilateral Loss of The Cardiophrenic Sinus Angle. *J Clin Anal Med* 2016;7(1): 42-5.